



RESEARCH ARTICLE

REVISED Anti-angiogenic effect of the combination of low-dose sorafenib and EGCG in HCC-induced Wistar rats [version 2; peer review: 2 approved with reservations]

Previously titled: Anti-angiogenic effect of the combination low-dose sorafenib and EGCG in HCC-induced Wistar rats

Andry Irawan¹, Erik Prabowo¹, Ignatius Riwanto¹, Wahyuni Lukita Atmodjo²

¹Department of Digestive Surgery, Diponegoro University, Semarang, Central Java, Indonesia

²Department of Anatomy, Pelita Harapan University, Tangerang, Banten, Indonesia

V2 First published: 09 Mar 2022, 11:289
<https://doi.org/10.12688/f1000research.109142.1>
Second version: 21 Nov 2022, 11:289
<https://doi.org/10.12688/f1000research.109142.2>
Latest published: 21 Dec 2022, 11:289
<https://doi.org/10.12688/f1000research.109142.3>

Abstract**Background:**

Sorafenib is a standard drug used for advanced hepatocellular carcinoma but is often resistant and toxic. Its combination with epigallo-3-catechin gallate leads to reduced resistance and toxicity but an equally effective anti-angiogenic effect. Therefore, this study aims to assess the anti-angiogenic effect of standard-dose Sorafenib compared to the combination of low-dose Sorafenib and epigallo-3-catechin gallate.

Methods:

We conducted an animal study and double-blind, randomized controlled trials. A total of 25 male Wistar rats (7-weeks-old) were randomly divided into four groups, namely Sham (K), Control (O), a combination of low-dose Sorafenib and epigallo-3-catechin gallate group (X1), and standard-dose Sorafenib group (X2). All groups were injected with N-Nitrosodiethylamine 70 mg/kg body weight (BW) intraperitoneally for ten weeks, except the Sham group. After the development of hepatocellular carcinoma, X1 and X2 were treated for two weeks. Subsequently, liver tissues were examined for vascular endothelial growth factor (VEGF) level and microvascular density expression.


Results:

There was a significant difference ($p=0.007$) in the level of VEGF between group X1 (low dose Sorafenib + EGCG) and X2 (Standard dose Sorafenib). However, the differences in VEGF levels of group X1 and X2 compared to group O(Control) were significantly lower, with values $p=0.000136$ and $p=0.019$, respectively. The expression of

Open Peer Review**Approval Status** ✓ ?

	1	2
version 3 (revision) 21 Dec 2022	✓ view	
version 2 (revision) 21 Nov 2022	↑ ? view	
version 1 09 Mar 2022	↑ ? view	? view

1. **Yefta Moenadjat** , Universitas Indonesia, Jakarta, Indonesia

2. **Andree Kurniawan** , Pelita Harapan University, Tangerang, Indonesia

Any reports and responses or comments on the article can be found at the end of the article.

microvascular density between groups X1 and X2 was not entirely different. Meanwhile, a significant difference ($p < 0.05$) was discovered when both groups were compared with the control group.

Conclusion:

The combination of low-dose Sorafenib with epigallo-3-catechin gallate is superior in reducing the level of VEGF compared to standard-dose Sorafenib and is better than the control. Standard-dose Sorafenib and the combination of low-dose Sorafenib and epigallo-3-catechin gallate have similar effectivity in reducing the expression of microvascular density and could prevent resistance and lower toxicity effects.

Keywords

Sorafenib, Epigallo-3-Catechin Gallate, Vascular Endothelial Growth Factor, Microvascular Density, N-Nitrosodiethylamine

Corresponding author: Andry Irawan (laparotomy85@gmail.com)

Author roles: **Irawan A:** Conceptualization, Data Curation, Formal Analysis, Funding Acquisition, Investigation, Methodology, Project Administration, Resources, Software, Supervision, Validation, Visualization, Writing – Original Draft Preparation, Writing – Review & Editing; **Prabowo E:** Conceptualization, Data Curation, Visualization, Writing – Original Draft Preparation, Writing – Review & Editing; **Riwanto I:** Conceptualization, Data Curation, Validation, Visualization, Writing – Original Draft Preparation, Writing – Review & Editing; **Atmodjo WL:** Formal Analysis, Resources, Supervision, Validation, Visualization, Writing – Original Draft Preparation, Writing – Review & Editing

Competing interests: No competing interests were disclosed.

Grant information: The author(s) declared that no grants were involved in supporting this work.

Copyright: © 2022 Irawan A *et al.* This is an open access article distributed under the terms of the [Creative Commons Attribution License](#), which permits unrestricted use, distribution, and reproduction in any medium, provided the original work is properly cited.

How to cite this article: Irawan A, Prabowo E, Riwanto I and Atmodjo WL. **Anti-angiogenic effect of the combination of low-dose sorafenib and EGCG in HCC-induced Wistar rats [version 2; peer review: 2 approved with reservations]** F1000Research 2022, 11:289 <https://doi.org/10.12688/f1000research.109142.2>

First published: 09 Mar 2022, 11:289 <https://doi.org/10.12688/f1000research.109142.1>

REVISED Amendments from Version 1

The title was revised for grammar. We made amendments in the abstracts section to clarify the abstract statement to be more relevant to the main manuscript. In the Introduction section, we explained the rationale for using Sorafenib, rats as the model, DEN in inducing HCC, and brief information on the toxicity and carcinogenesis. In the Method section, we mentioned the preparation of animals and pre-prevention treatment. We have revised and incorporated several concerns regarding the role of lenvatinib and its implication for clinical practice on the combination of experimental drugs.

Any further responses from the reviewers can be found at the end of the article

Introduction

Hepatocellular carcinoma (HCC) is the most common primary type of liver cancer. In 2013, the prevalence of liver and bile duct cancer in a developed country like the United States was 30,640.^{1,2} A high incidence of HCC was discovered in South and East Asia, Central and West Africa, Melanesia, and Micronesia/Polynesia. It has been estimated that there are more than 749,000 new cases of HCC in men and 226,000 in women every year.^{3,4} In 2020, liver cancer was considered the sixth most common cancer and the third leading to cancer-related death worldwide.⁵

Vascular endothelial growth factors (VEGF) are essential in HCC tumor growth. Several carcinogens and tumor promoters initiate inappropriate activation of nuclear factor kappa B (NF- κ B), which mediates the inflammation process and tumorigenesis. Meanwhile, overexpression of VEGF increases blood vessel permeability, leading to the differences between oxygen flow and delivery. A high level of VEGF is also typical in chronic liver disease that often triggers HCC.^{6,7} Micro-vessel density (MVD) is a tumor indicator of angiogenesis that needs to be examined in HCC since a higher level of MVD shows a poor prognosis. This high angiogenic activity can be inhibited through the administration of anti-angiogenic drugs.⁸

The most common management of HCC for operable cancers is liver resection, while chemotherapy and targeted therapy are also used. It was discovered that 80% of HCC patients are diagnosed with advanced-stage or inoperable cancer. Systemic treatment with Sorafenib is required to change the condition at the operable stage. Sorafenib has been proven to be the first systemic therapy that successfully improved HCC patients' survival rate. It is an oral multi-kinase inhibitor that targets vascular endothelial growth factor receptor (VEGFR)-1, VEGFR-2, and VEGFR-3 thereby reducing tumor angiogenesis. The disadvantages of Sorafenib treatment include high cost, and approximately 30% of all patients responded to the treatment. Monotherapy of Sorafenib can cause several patient complaints, resistance, and increased charges; therefore, when given at a low dose and in combination with herbal medicines, the same effect is expected, which is more affordable in price.⁹⁻¹²

Epigallocatechin-3-gallate (EGCG) from Sigma-Aldrich is an active ingredient that was proven to prevent the growth of blood vessels in experimental animals. Its mechanism of action is by inhibiting urokinase and tyrosine kinase, which activates VEGF, epidermal growth factor (EGF), and fibroblast growth factor (FGF).¹³ In 2005, a previous study in Japan stated that EGCG induces both *in vitro* and *in vivo* liver cell apoptosis to improve the prognosis of HCC. *In vitro* studies showed that the effective level of EGCG varies from 1 to 100 mol/L. According to pre-clinical studies in rats, less than 5% of oral catechin taken as a tea constituent can reach systemic circulation; therefore, intraperitoneally administration is considered more effective. EGCG is the right choice to be combined with Sorafenib in advanced HCC, which uses the synergism of the two drugs. This combination can lead to similar effects as the Sorafenib standard dose.^{14,15}

Therefore, this study investigates the effectiveness of anti-angiogenic activity between Sorafenib standard dose and the low dosage of Sorafenib with EGCG. It was presented in adherence to the checklist of ARRIVE reporting guidelines.

Methods**Induction of HCC in animals and experimental design**

This study used a randomized, double-blind control trial post-test only design method performed by laboratory analysts (Figure 1). Preparation of Wistar rats began with acclimatization for three weeks in the Mochtar Riadi Institute of Nanotechnology animal laboratory. A total of 25 male Wistar rats (PT Biomedical Technology Indonesia), seven weeks old with bodyweight 200–250 grams, were placed in a cage with a controlled temperature of 22°C under 12 hours of light and dark cycle. The rats were given free access to food with AIN76 standard dietary formula for rodents, which was 67.7% carbohydrates, 11.5% lipids, and 20.8% protein from the Food Engineering Laboratory, IPB, Bogor, Indonesia, purchased from PT Surya Science and Beverages.

Diethyl-Nitrosamine (DEN) (N0756) with a molecular weight of 102.14 and Epigallocatechin-3-O-Gallate (Y0001936; primary pharmaceutical grade standard) with a molecular weight of 458.37 was purchased from Sigma-Aldrich.

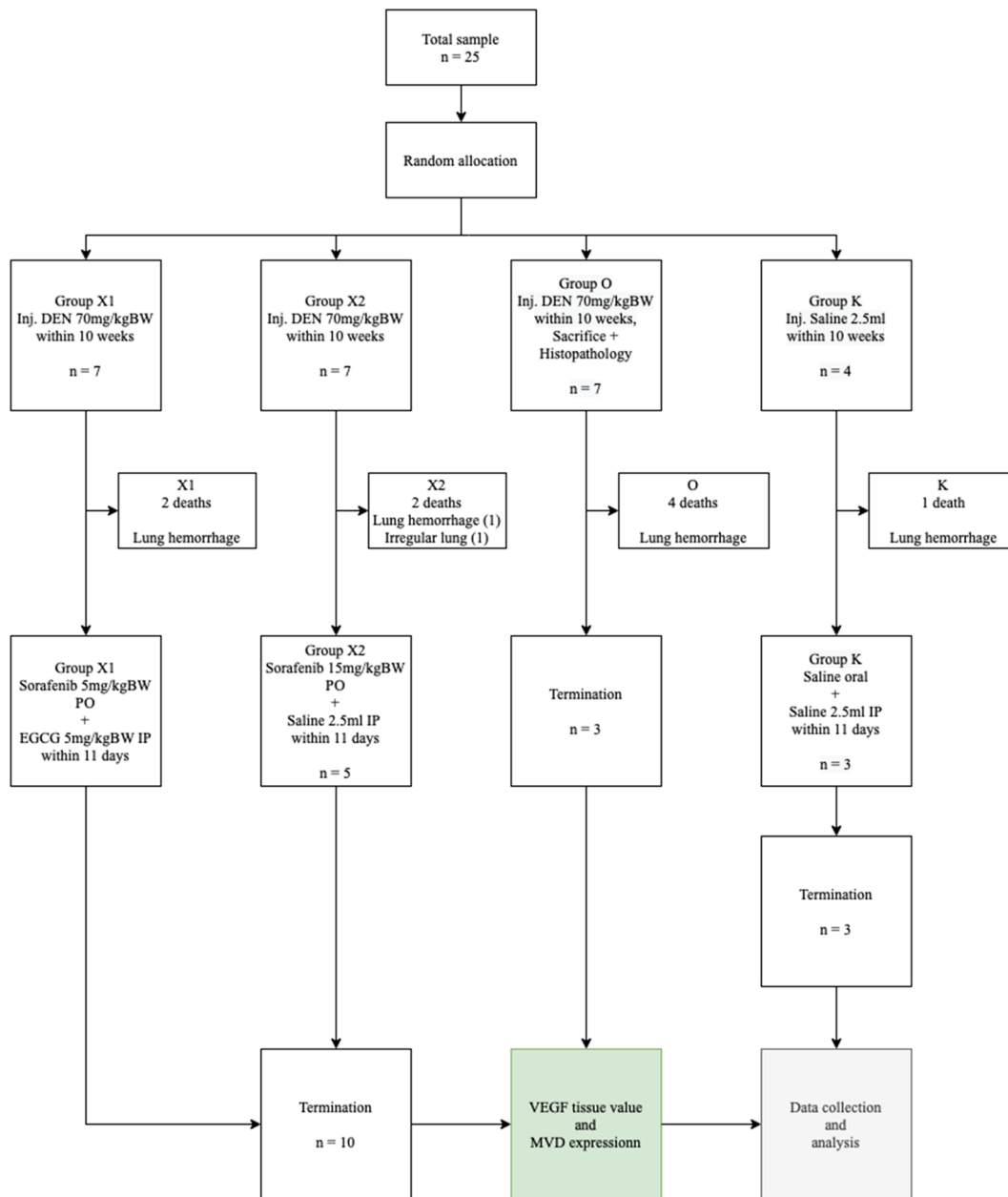


Figure 1. Consolidated report. DEN: Diethyl-Nitrosamine, EGCG: Epigallocatechin-3-gallate, MVD: Micro-vessel density, VEGF: Vascular endothelial growth factor.

In contrast, each tablet of Sorafenib contains 200 mg of Tosylate (Nexavar). The DNA-carcinogen complexes resulted from the interaction between DEN and DNA through the formation of the covalent bonds. Then, DEN will induce chronic inflammation and fibrosis. The DEN-induced rat model was believed to contribute to immune response and tumor microenvironment in hepatocarcinogenesis. The characterization of anti-tumor adaptive immune response and the role of T and B cells was used to control tumor formation and progression. Under a microscope, a solid growth pattern with anaplastic cells, pleomorphic, dense chromatin, and nucleolus prominent with invasive growth into stroma was seen as similar to HCC. Consequently, genotoxic carcinogens are the most frequently used to induce HCC in Wistar rats.^{16–20}

This study followed the National Institutes of Health Guidelines for the Care and Use of Laboratory Animals. It was approved by Mochtar Riady Institute for Nanotechnology Ethics Committee (MRIN EC) with protocol number 2101001-AS06. The inclusion criteria were healthy and active 7-week-old male Wistar rats weighing 200–250 grams, while unhealthy male Wistar rats with anatomical anomalies were excluded. Any infected or dead Wistar rats were also

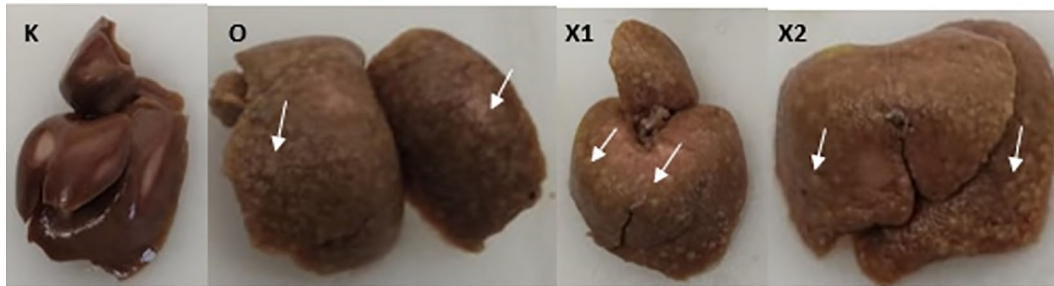


Figure 2. After ten weeks of Diethyl-Nitrosamine (DEN) 70 mg/kg BW intraperitoneal injection, macroscopic liver tissue. Group X1, X2, and O present multiple white nodules (White arrow); group (K) did not develop any nodules.

dropped out during the experiment. We chose Wistar rats due to their short lifespan and breeding capacity. On the other hand, the metabolizing pathways induced by DEN in Wistar rats were similar to humans. Thus, this model was important in our research.^{21,22}

The sample size was calculated using the degree of freedom (Minimum and Maximum sample) formula. Rats were randomized and allocated into four groups, consisting of 7 rats, except the control (K) group, which contained four rats, with a minimal sample size of three. Subsequently, DEN was injected intraperitoneally in the abdominal area below the umbilicus on 21 rats for two treatment groups and a control group, with 70 mg/kg BW/week for ten weeks.^{23,24} After ten weeks, all rats were randomly divided into four groups, namely sham (K), Sorafenib 5 mg/kg BW + EGCG 5 mg/kg BW (X1), Sorafenib 15 mg/kg BW (X2), and without treatment (Group O). Group K was injected with saline for ten weeks, parallel with other groups. After the administration of DEN, group O was sacrificed, and a pathologist from Dr. Mintoharjo Naval Hospital performed a histopathological examination of liver tissue to show the formation of HCC. Anaplastic cells, oval nuclei, pleomorphic, coarse chromatin, and nucleolus invasive growth into stroma were observed during the examination, which confirmed HCC. The success of the induction process was determined within ten weeks.

Sorafenib was dissolved in a maximum of 1.5 mL saline (maximum 10 mL/kg BW/day) and administered orally at 5 mg/kg BW and 15 mg/kg BW. Subsequently, EGCG 5 mg/kg BW/day was dissolved in approximately 1.5 mL saline (maximum 20 mL/kg BW/day) and administered by intraperitoneal injection once a day for 14 days. The sham group (K) was administered a saline solution orally and intraperitoneally, while the sorafenib-only group (X2) received intraperitoneal saline and oral Sorafenib. Meanwhile, the combination group of EGCG and Sorafenib (X1) received intraperitoneal EGCG and oral Sorafenib, and the bodyweight of the rats was measured once a week. At the end of the experiment, the rats were sacrificed, and exsanguination was done on deeply anesthetized animals with ketamine 80 mg/kg BW and xylazine 100 mg/kg BW intramuscularly to alleviate any suffering. The liver tissues were resected and examined microscopically. Moreover, a veterinarian performed a necropsy when any rat died during the experiment to investigate the cause of death (Figure 2).

In liver tissue, VEGF was evaluated using an enzyme-linked immunosorbent assay (ELISA) quantitative methods, while MVD was calculated using Immunohistochemistry (IHC). The intensity and area of sinusoidal endothelial staining were measured quantitatively using a microscope at 100× magnification. Furthermore, the hot spots from the immunohistochemistry were selected using the “color selection” function and the “area/density (intensity)” function (ImageJ, RRID: SCR_003070) to calculate the level.

ELISA for tissue VEGF

To prepare lysate from tissue, tissue of interest was dissected with clean tools. Dissected tissue was placed in microcentrifuge or Eppendorf tubes. Lysis buffer consisting of NP-40 buffer, sodium chloride, NP-40, Tris pH 8.0, and Triton X-100 or NP-40) was added to 5 mg of tissue and homogenized rapidly. Next, it was centrifuged at 4°C for 20 minutes. After carefully removing the tubes and placing them on ice, any supernatant was aspirated, and the pellet was discarded.^{25,26}

A Bradford, a Lowry, or a bicinchoninic acid (BCA) assay was conducted to calculate protein level. Bovine Serum Albumin (BSA) is usually used as a standard protein. Each sample was frozen at -20°C for immunoprecipitation. 200µL of 1X Bradford reagent, five µL of BSA, and 30 µL of the unknown model were added to each test tube. Absorbance was determined using a sipper or individual cuvettes at 595 (VIS lamp).

All standards and samples were prepared twice as recommended and stored at room temperature. Each well-containing standard and sample were incubated for 2.5 hours at room temperature. The washing process using 300 μ L of Wash Buffer was repeated four times. All liquid was eliminated after each step to achieve the best result. After the last wash, the plate was inverted and blotted using a paper towel.

Approximately 100 μ L of 1 \times Detection Antibody was titrated and incubated at room temperature for one hour. All liquid was removed, and 100 μ L of Streptavidin solution was added and incubated at room temperature for 45 minutes. Approximately 100 μ L of TMB One-Step Substrate Reagent (Item H) was added and set in dark condition for 30 minutes. Lastly, 50 μ L of Stop Solution (Item I) was added, and absorbance was recorded at 450 nm.

Immunohistochemistry for MVD

Deparaffinization was done in the incubator at 60°C for 45 minutes, followed by deparaffinization in xylene for 10 minutes. Next, 96% ethanol, 80% ethanol, and 70% ethanol were added to the formalin-fixed paraffin-embedded tissue for 5 minutes. The tissue was washed using distilled water. Antigen retrieval buffer (citrate buffer + tween) was placed into a jar and microwaved at full power for 20 minutes. The pot was removed and chilled on ice for 20 minutes.

Several drops of Hydrogen Peroxide Block were added to the section, incubated for 10 minutes, and rinsed in buffer twice. Protein Block was added, set for 10 minutes, and rinsed once in the buffer. Primary MVD polyclonal antibody (MBS 2520154) from Abcam was added (1:100) in PBS-T, incubated at 4°C for 2 hours, and rinsed four times in buffer. A Biotinylated Goat Anti-Polyvalent was added, set for 10 minutes, and rinsed four times in buffer. Streptavidin Peroxidase was added, incubated for 10 minutes, and rinsed four times in buffer.

Approximately 30 μ L of DAB Chromogen was applied into 1.5 mL of DAB Substrate. It was incubated for 3 seconds and rinsed four times in the buffer. Next, Hematoxylin was used as a counterstain, incubated for 20 minutes, and rinsed in tap water. Tissues were dehydrated using 70% ethanol, 80% ethanol, and 96% ethanol, each for 1 minute. The samples were observed under 10 \times , 40 \times , and 100 \times magnification.²⁷ For MVD, the Spearman's correlation coefficient (ρ) was 0.93 ($p < 0.01$), while intra-observer agreement (Kappa) were 0.88 for cut-off using mean.^{28,29}

Statistical analysis

All data were expressed as mean \pm standard deviation of the mean. The statistical analysis was conducted using SPSS 28 (IBM SPSS Statistics, RRID:SCR_019096). All data were normally distributed, and the comparisons between groups were analyzed using ANOVA. *Post hoc* analysis using the least significant difference (LSD), where a p-value < 0.05 was considered statistically significant.

Results

This study showed that the Sorafenib-only group effectively reduced VEGF tissue levels better than the treatment group. However, there was no significant difference in lowering MVD expression compared to the low-dose Sorafenib and EGCG group, which indicated better overall results than the Sorafenib-only group. During the experiment, nine rats died due to pulmonary hemorrhage, and one died of irregular lung surface.

A total of 13 rats survived the 11 weeks of the experiment, although some looked unhealthy. One group reached the minimum sample size based on the calculation of the degree of freedom, the Institutional Animal Care and Use Committee (IACUC) Guidebook, and the World Health Organization (WHO). At the end of the experiment, the whole group of mice was terminated according to the euthanasia techniques based on IACUC and the American Veterinary Medical Association (AVMA) Guidelines.

Data characteristic

The Shapiro-Wilk test results were used to calculate the mean and the distribution of the rats' body weight data, and $p > 0.05$ was obtained for all groups. Homogeneity test results with Levene's test obtained $p = 0.978$, which showed that the data obtained is homogeneous.

The 16 sample slides revealed that the tumor growth was solid, with anaplastic cells having round, oval, pleomorphic nuclei, coarse chromatin, and prominent nucleolus that grows invasively into the stroma (Figure 3).

VEGF level

The mean VEGF level (Figure 4) between group Sorafenib 5 mg/kg BW + EGCG 5 mg/kg BW (X1) (106.682 ± 41.024) and group Sorafenib 15 mg/kg BW (X2) (214.5162 ± 67.717) had significant difference ($p < 0.05$), which showed that group X1 had the most potent effect in reducing VEGF level. Furthermore, the VEGF levels between group X1 and the

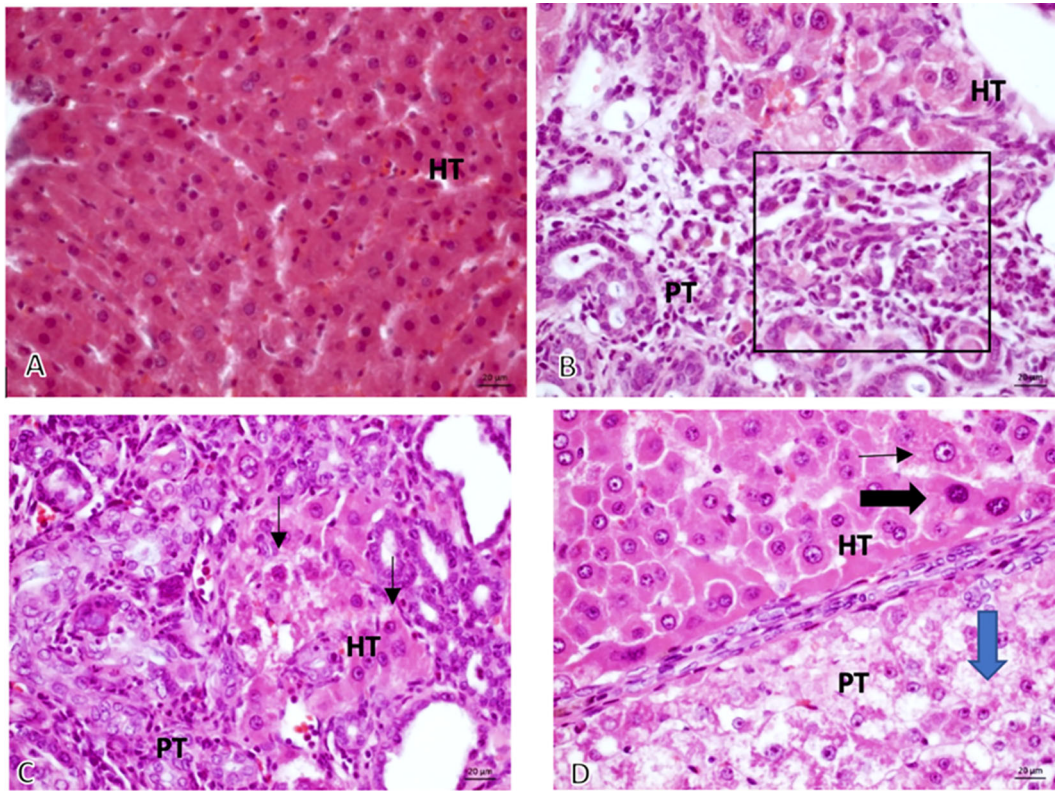


Figure 3. The validation of HCC. Microscopic 40× magnification on non-induced Diethyl-Nitrosamine (DEN) group: (A, Group K) normal hepatocyte; comparing graphic on DEN induced group: (B, Group O) Bile Duct hyperplasia (Black square area); (C, Group X1) Hyperchromatic cells (black arrow) and (D, Group X2) Prominent cell (thin-arrow), Hyperchromatic cell (thick black - arrow), Ballooning degeneration (Blue-Arrow). HT, Hepatocyte; PT, Porta tract.

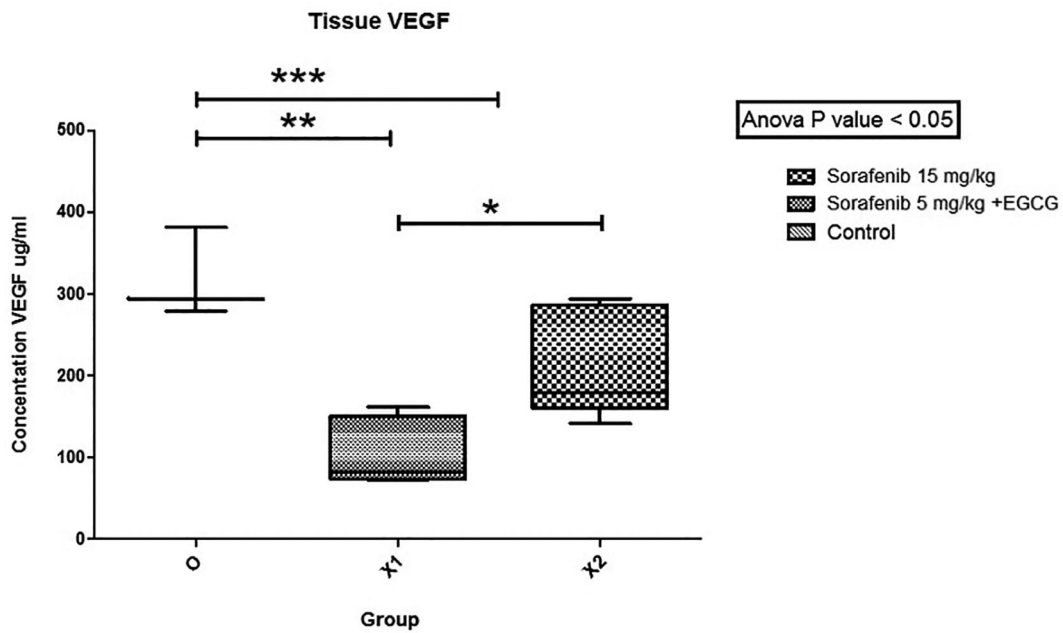


Figure 4. The tissue VEGF level. There was a significant difference in the level of VEGF in group X1 compared to X2 (*). Between groups X1 and O, VEGF was significantly different (**). Between-group X2 and O, VEGF was significantly different (***) ($p < 0.05$).

group without treatment (O) (318.101 ± 55.078) were significantly different ($p < 0.05$). A similar result was seen since the VEGF level between groups X2 and O were quite different ($p < 0.05$).

MVD expression

MVD evaluation was performed using $10\times$ and $40\times$ magnification to measure the intensity and area of sinusoidal endothelial staining (Figure 5). Subsequently, the hot spots from the immunohistochemistry were selected, and levels were calculated. The mean MVD expression between the group Sorafenib 5 mg/kg BW + EGCG 5 mg/kg BW (X1) (36 ± 4.416) and group Sorafenib 15 mg/kg BW (X2) (26.2 ± 4.55) had no significant difference. Based on the results, MVD expression (Figure 6) between all groups and group O (176 ± 19) showed a significant difference ($p < 0.05$).

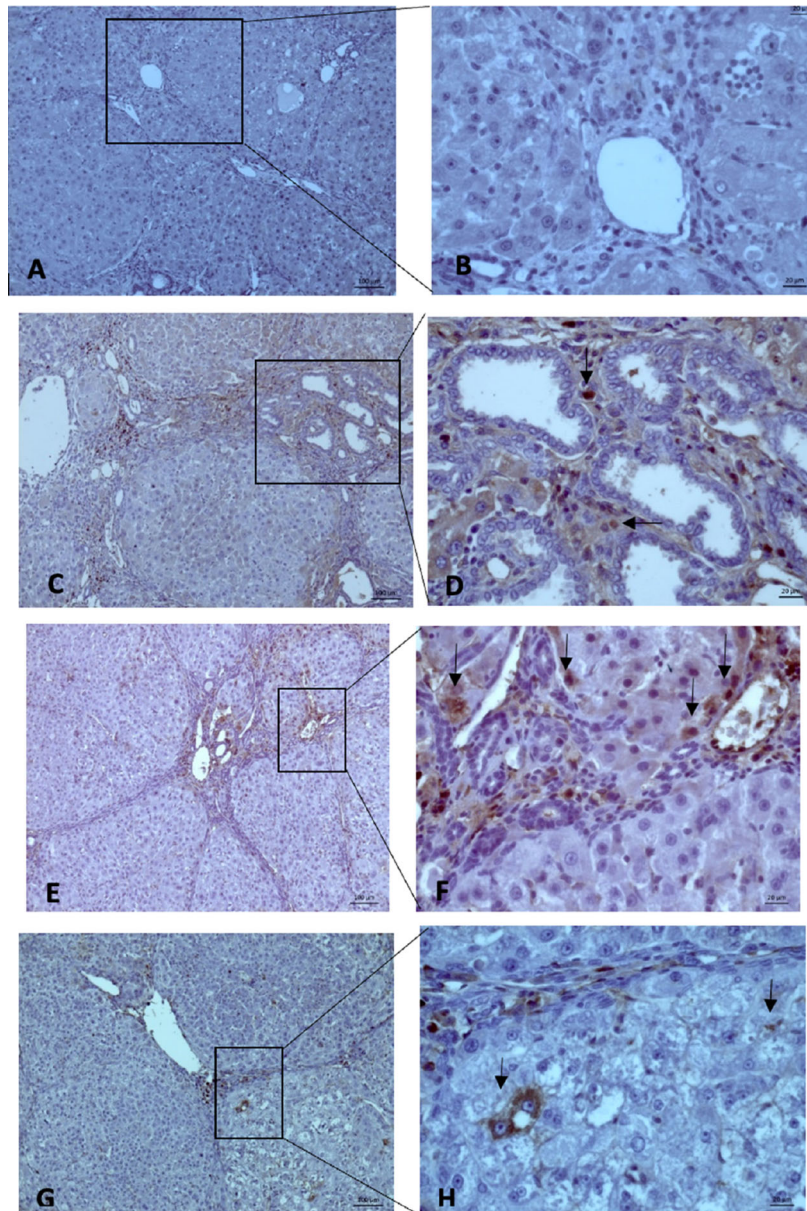


Figure 5. The MVD expression on microscope $10\times$ (left side) and $40\times$ magnification (right side): (A-B) (Group Sham) no finding of "Hot Spot" area on hepatocyte endothelial sinusoid; (C-D) (Group O) showed brown spot (black-arrow); (E-F) (Group X1) and (G-H) (Group X2) we found the same result (Black-Arrow). All three groups showed a "hot spot" area, which means there were positive results.

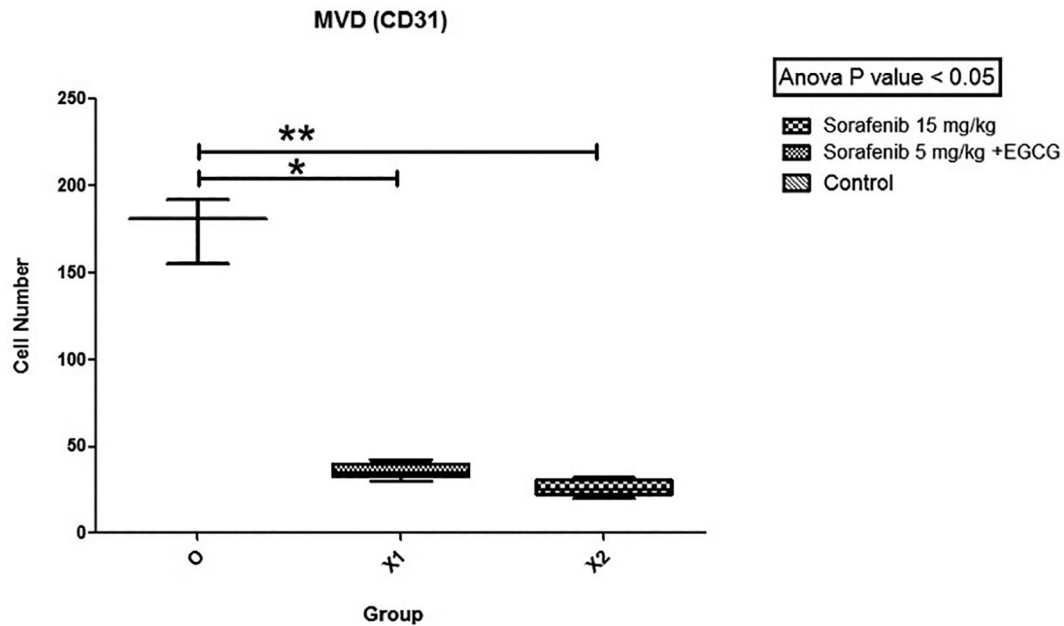


Figure 6. The MVD expression. There was no significant difference in the expression of MVD between group X1 and X2, but both X1 and X2 were significantly different compared to the control group (O) (non-treatment group) with ($p < 0.05$).

Discussion

This study showed that the benefits of the combination of Sorafenib and EGCG are the same as an anti-neoplastic drug, which is as effective as anti-angiogenic. The results of VEGF levels between 2 groups, namely the combination group Sorafenib 5 mg/kg BW and EGCG 5 mg/kg BW (X1) compared with Sorafenib 15 mg/kg BW alone (X2), showed that both treatments could reduce VEGF level. However, the X1 group was significantly more potent in decreasing VEGF value than group X2. This has exceeded the expectations, where the combination of low-dose Sorafenib and EGCG was more effective than only standard-dose Sorafenib. This indicated that Sorafenib and EGCG act synergistically with a strengthening effect in anti-angiogenesis.

In vivo and *in vitro* studies have proved the effect of EGCG as a chemo-preventive, anti-angiogenic, anti-invasive, anti-proliferative, anti-inflammatory, and antioxidant substance. It was shown that EGCG blocks NF- κ B activation by inhibiting I κ B α degradation and the mitogen-activated protein kinase (MAPK) pathway. Meanwhile, downregulation of inducible nitric oxide synthase (iNOS) transcription and nitric oxide (NO) production from macrophages depends on NF- κ B inhibition. It was reported that EGCG blocks NF- κ B activation in human endothelial cells and inhibits monocyte chemotactic protein-1 (MCP-1) expression. Similarly, EGCG also prevents the apoptosis process by reducing mRNA expression of Bax and caspase three activity. It also inhibits cyclooxygenase-2 (COX-2) expression, proteasome-dependent degradation, MAPK pathways, and growth factor-dependent signaling, namely insulin-like growth factor-I (IGF-I), VEGF, and EGF.²⁹

The results also suggested that several factors are responsible for the less effective administration of Sorafenib as a single drug. Firstly, Sorafenib is accumulated in cancer cells, followed by an increase in the expression of enzymes to metabolize Sorafenib, which affects drug exposure. Thirdly, the presence or absence of tumor influences the level of Sorafenib and its primary metabolites based on assessing resistance to Sorafenib administration.³⁰

MVD expression was significantly different between X1 and X2 groups compared to group O. This showed that the combination of low-dose Sorafenib and EGCG is also effective as standard-dose Sorafenib-only by decreasing MVD expression intratumorally. However, there is no significant difference in the discovery of MVD expression between the X1 and X2 groups. These are influenced by time length because the formation of MVD is affected by the growth of the capsule in the tumor. This is in line with Kuczynski EA *et al.*, who showed that therapy with Sorafenib significantly inhibits MVD ($p < 0.001$ vs. controls). In contrast, the Sorafenib-resistant group showed no evidence of continued angiogenesis.³¹ The evaluation of MVD expression is critical to determine the prognosis. According to Poon RTP *et al.*, MVD-CD34 tumors were the only significant predictor of disease-free survival in patients with HCC or tumor size < 5 cm.³²

Although the result differed from the hypothesis, a very satisfying conclusion was successfully obtained. The combination of low-dose Sorafenib with EGCG had better effectiveness than the standard dose of Sorafenib in lowering VEGF levels and was equally effective in reducing MVD expression in Wistar rats induced by DEN. Based on the results, it was concluded that EGCG adds a supplementary anti-angiogenic effect for HCC. Therefore, using low-dose Sorafenib combined with EGCG is a more cost-effective therapy recommended to increase drug compliance potentially. Similarly, it also provides a satisfying therapeutic effect for advanced HCC.

After ten weeks of administering DEN 70 mg/kg, macroscopic gross liver tissues showed irregular surfaces and pale colors. The histopathologists also confirmed HCC characteristics. The length and dosage of DEN induction were in line with Atmodjo *et al.*, while the liver carcinogenesis or the beginning of HCC was recorded.³³ There was a force majeure event in the experimental animal since nine rats were found dead. Meanwhile, eight rats died from pulmonary hemorrhage, and one died with irregular lung surface due to lung injury. The hypothesis of this study stated that the suppression of the immune system increased the probability of lung disorders due to respiratory infections, fibrosis, or early malignancy in the lungs when rats were injected with DEN.³⁴ This is because one rat was not administered DEN died due to lung hemorrhage. This can be explained by Kun MW *et al.*, who discovered the other cause of Wistar rat's lung problem was lung infection due to *A. Cantonensis*.³⁵ *M. Pulmonis* causes a different type of infection, as explained by the study of Chawla *et al.*, which showed gross and histopathological discoveries of severe congestion of the lungs with suppurative and necrotizing pneumonia.³⁶ Wang Y *et al.* also evaluated the induction effect of DEN in a rat model. They discovered that the induced rat had liver dysfunction and damage, characterized by diffuse lesions with extensive interstitial inflammatory cell infiltration, alveolar edema, and bleeding. Meanwhile, minor injuries were discovered in the spleen, kidney, large intestine, heart, and other organs.³⁷ Atmodjo *et al.* also noted the same discoveries for lung hemorrhage.³³

There are several limitations to this study; firstly, the unhealthy condition of the samples after ten weeks of administration of DEN can affect the number of samples. This led to the consideration of the decision of earlier termination. Secondly, the method of administering EGCG was unclear with the best effectiveness, oral EGCG, which is associated with poor absorption (<5% absorption rate). Therefore, the intraperitoneal injection method was used to administer EGCG. This study recommends further investigation of whether the administration of EGCG in the form of nanoparticles orally or parenterally can increase the absorption and bioavailability of EGCG in the intestine and plasma.^{12,13}

Conclusion

The combination of low-dose Sorafenib with EGCG has a more potential anti-angiogenic effect on liver cancer by reducing VEGF levels compared to the single standard-dose Sorafenib. It also has similar effectiveness as single standard-dose Sorafenib in reducing MVD expression compared to the control group. Meanwhile, further study on the anti-angiogenic effect of low-dose sorafenib combined with EGCG is recommended to evaluate resistance and Toxicity.

Data availability

Underlying data

Zenodo: Underlying data for 'Anti-angiogenic effect of the combination low-dose sorafenib and EGCG in HCC-induced Wistar rats.' <https://doi.org/10.5281/zenodo.6044890>.

This project contains the following underlying data:

- VEGF and MVD raw data.xlsx (dataset)

Reporting guidelines

Zenodo: ARRIVE checklist for 'Anti-angiogenic effect of the combination low-dose sorafenib and EGCG in HCC-induced Wistar rats.' <https://doi.org/10.5281/zenodo.6044890>.

Data are available under the terms of the [Creative Commons Zero "No rights reserved" data waiver](#) (CC0 4.0 Public domain dedication).

Authors' contributions

Conception and design: Andry Irawan, Erik Prabowo, Ignatius Riwanto

Administrative support: Andry Irawan, Erik Prabowo, Wahyuni Lukita Atmodjo

Provision of study materials or patients: Wahyuni Lukita Atmodjo

Collection and assembly of data: Andry Irawan

Data analysis and interpretation: Ignatius Riwanto, Wahyuni Lukita Atmodjo

Manuscript writing: All authors

Final approval of manuscript: All authors

Acknowledgments

We thank Pelita Harapan University for facilitating this study and Dr. Ricarhdo Valentino Hanafi for organizing the manuscript.

References

- Centers for Disease Control and Prevention (CDC): **Hepatocellular carcinoma - United States, 2001-2006**. *MMWR Morb. Mortal. Wkly. Rep.* 2010; **59**(17): 517-520.
- Crissien AM, Frenette C: **Current management of hepatocellular carcinoma**. *Gastroenterol. Hepatol. (N Y)*. 2014; **10**(3): 153-161. [PubMed Abstract](#)
- Ferlay J, Shin HR, Bray F, *et al.*: **Estimates of worldwide burden of cancer in 2008: GLOBOCAN 2008**. *Int. J. Cancer*. 2010; **127**(12): 2893-2917. [PubMed Abstract](#) | [Publisher Full Text](#)
- Shimizu M, Shirakami Y, Sakai H, *et al.*: **Chemo-preventive potential of green tea catechins in hepatocellular carcinoma**. *Int. J. Mol. Sci.* 2015; **16**(3): 6124-6139. [PubMed Abstract](#) | [Publisher Full Text](#)
- International Agency for Research on Cancer: *Liver*. World Health Organization; 2020. Accessed: January 30, 2021. [Reference Source](#)
- Jain RK, Tong RT, Munn LL: **Effect of vascular normalization by anti-angiogenic therapy on interstitial hypertension, peritumor edema, and lymphatic metastasis: insights from a mathematical model**. *Cancer Res.* 2007; **67**(6): 2729-2735. [PubMed Abstract](#) | [Publisher Full Text](#)
- Amarapurkar AD, Amarapurkar DN, Vibhav S, *et al.*: **Angiogenesis in chronic liver disease**. *Ann. Hepatol.* 2007; **6**: 170-173. [Publisher Full Text](#)
- Bösmüller H, Pfefferle V, Bittar Z, *et al.*: **Microvessel density and angiogenesis in primary hepatic malignancies: Differential expression of CD31 and VEGFR-2 in hepatocellular carcinoma and intrahepatic cholangiocarcinoma**. *Pathol. Res. Pract.* 2018; **214**(8): 1136-1141. [PubMed Abstract](#) | [Publisher Full Text](#)
- Sun HC, Tang ZY: **Angiogenesis in hepatocellular carcinoma: the retrospectives and perspectives**. *J. Cancer Res. Clin. Oncol.* 2004; **130**: 307-319. [PubMed Abstract](#) | [Publisher Full Text](#)
- Llovet JM, Ricci S, Mazzaferro V: **Sorafenib in advanced hepatocellular carcinoma**. *N. Engl. J. Med.* 2008; **359**(4): 378-390. [Publisher Full Text](#)
- MacGregor JL, Silvers DN, Grossman ME, *et al.*: **Sorafenib-induced erythema multiforme**. *J. Am. Acad. Dermatol.* 2007; **56**: 527-528. [PubMed Abstract](#) | [Publisher Full Text](#)
- Cao Y, Cao R: **Angiogenesis inhibited by drinking tea**. *Nature*. 1999; **398**(6726): 381. [PubMed Abstract](#) | [Publisher Full Text](#)
- Fassina G, Vene R, Morini M, *et al.*: **Mechanism of inhibition of tumor angiogenesis and vascular tumor growth by epigallocatechin 3 gallate**. *Clin. Cancer Res.* 2004; **10**: 4865-4873. [PubMed Abstract](#) | [Publisher Full Text](#)
- Li Y, Chang SC, Goldstein BY, *et al.*: **Green tea consumption, inflammation and the risk of primary hepatocellular carcinoma in a Chinese population**. *Cancer Epidemiol.* 2011; **35**: 362-368. [PubMed Abstract](#) | [Publisher Full Text](#)
- Nishikawa T, Nakajima T, Moriguchi M, *et al.*: **A green tea polyphenol, epigallocatechin-3-gallate, induces apoptosis of human hepatocellular carcinoma, possibly through inhibition of Bcl-2 family proteins**. *J. Hepatol.* 2006; **44**(6): 1074-1082. [PubMed Abstract](#) | [Publisher Full Text](#)
- Verna L, Whysner J, Williams GM: **N-nitrosodiethylamine mechanistic data and risk assessment: bioactivation, DNA-adduct formation, mutagenicity, and tumor initiation**. *Pharmacol. Ther.* 1996; **71**(1-2): 57-81.
- Dapito DH, Mencin A, Gwak GY, *et al.*: **Promotion of hepatocellular carcinoma by the intestinal microbiota and TLR4**. *Cancer Cell.* 2012 Apr 17; **21**(4): 504-516.
- Schneider C, Teufel A, Yevsa T, *et al.*: **Adaptive immunity suppresses formation and progression of diethylnitrosamine-induced liver cancer**. *Gut.* 2012 Dec; **61**(12): 1733-1743.
- Jilkova ZM, Kuyucu AZ, Kurma K, *et al.*: **Combination of AKT inhibitor ARQ 092 and sorafenib potentiates inhibition of tumor progression in cirrhotic rat model of hepatocellular carcinoma**. *Oncotarget.* 2018 Jan 23; **9**(13): 11145-11158.
- Zhang HL, Yu LX, Yang W, *et al.*: **Profound impact of gut homeostasis on chemically-induced pro-tumorigenic inflammation and hepatocarcinogenesis in rats**. *J. Hepatol.* 2012 Oct; **57**(4): 803-812.
- Heindryckx F, Colle I, Van Vlierberghe H: **Experimental mouse models for hepatocellular carcinoma research**. *Int. J. Exp. Pathol.* 2009 Aug; **90**(4): 367-386.
- Yoo JS, Guengerich FP, Yang CS: **Metabolism of N-nitrosodialkylamines by human liver microsomes**. *Cancer Res.* 1988 Mar 15; **48**(6): 1499-1504.
- Nishida H, Omori M, Fukutomi Y, *et al.*: **Inhibitory effects of (-)-epigallocatechin gallate on spontaneous hepatoma in C3H/HeNcrj mice and human hepatoma-derived PLC/PRF/5 cells**. *Jpn. J. Cancer Res.* 1994; **85**: 221-225. [PubMed Abstract](#) | [Publisher Full Text](#) | [Free Full Text](#)
- Arifin WN, Zahiruddin WM: **Sample Size Calculation in Animal Studies Using Resource Equation Approach**. *Malays. J. Med. Sci.* 2017; **24**(5): 101-105. [PubMed Abstract](#) | [Publisher Full Text](#)
- Mathonnet M, Descottes B, Valleix D, *et al.*: **VEGF in hepatocellular carcinoma and surrounding cirrhotic liver tissues**. *World J. Gastroenterol.* 2006; **12**(5): 830-831. [PubMed Abstract](#) | [Publisher Full Text](#) | [Free Full Text](#)
- Landriscina M, Cassano A, Ratto C, *et al.*: **Quantitative analysis of basic fibroblast growth factor and vascular endothelial growth factor in human colorectal cancer**. *Br. J. Cancer.* 1998; **78**(6): 765-770. [PubMed Abstract](#) | [Publisher Full Text](#) | [Free Full Text](#)
- Viera AJ, Garrett JM: **Understanding interobserver agreement: the kappa statistic**. *Fam. Med.* 2005; **37**(5): 360-363. [PubMed Abstract](#)
- Agnani B, Solanki R, Ansari M, *et al.*: **Prognostic Significance of Microvessel Density as Assessed by anti CD34 Monoclonal**

- Antibody in Invasive Ductal Carcinoma of Breast.** *Asian Pac. J. Cancer Prev.* 2021; **5**(3): 75–79.
29. Jantan I, Ahmad W, Bukhari SNA: **Plant-derived immunomodulators: an insight on their pre-clinical evaluation and clinical trials.** *Front. Plant Sci.* 2015; **6**: 1–18.
30. Rochat B: **Role of cytochrome P450 activity in the fate of anticancer agents and in drug resistance: focus on tamoxifen, paclitaxel and imatinib metabolism.** *Clin. Pharmacokint.* 2005; **44**: 349–366.
[PubMed Abstract](#) | [Publisher Full Text](#)
31. Kuczynski EA, Lee CR, Man S, *et al.*: **Effects of Sorafenib Dose on Acquired Reversible Resistance and Toxicity in Hepatocellular Carcinoma.** *Cancer Res.* 2015; **75**: 2510–2519.
[PubMed Abstract](#) | [Publisher Full Text](#)
32. Poon RT, Ng IO, Lau C, *et al.*: **Tumour microvessel density as a predictor of recurrence after resection of hepatocellular carcinoma: a prospective study.** *J. Clin. Oncol.* 2002; **20**: 1775–1785.
[PubMed Abstract](#) | [Publisher Full Text](#)
33. Atmodjo WL, Larasati YO, Isbandiati D, *et al.*: **Curcuminoids Suppress the Number of Transformed-Hepatocytes and Ki67 Expression in Mice Liver Carcinogenesis Induced by Diethylnitrosamine.** *J. Can. Sci. Res.* 2018; **3**: 2.
34. Burkholder T, Foltz C, Karlsson E, *et al.*: **Health Evaluation of Experimental Laboratory Mice.** *Curr. Protoc. Mouse. Biol.* 2012; **2**: 145–165.
[PubMed Abstract](#) | [Publisher Full Text](#)
35. Wun MK, Davies S, Spielman D, *et al.*: **Gross, microscopic, radiologic, echocardiographic and haematological findings in rats experimentally infected with *Angiostrongylus cantonensis*.** *Parasitology.* 2021; **148**(2): 159–166.
[PubMed Abstract](#) | [Publisher Full Text](#)
36. Chawla S, Jena S, Venkatsan B, *et al.*: **Clinical, pathological, and molecular investigation of *Mycoplasma pulmonis*-induced murine respiratory mycoplasmosis in a rat (*Rattus norvegicus*) colony.** *Vet. World.* 2017; **10**(11): 1378–1382.
37. Wang Y, Liang H, Jin F, *et al.*: **Injured liver-released miRNA-122 elicits acute pulmonary inflammation via activating alveolar macrophage TLR7 signaling pathway.** *Proc. Natl. Acad. Sci. U S A.* 2019; **116**(13): 6162–6171.

Open Peer Review

Current Peer Review Status: ? ?

Version 2

Reviewer Report 25 November 2022

<https://doi.org/10.5256/f1000research.138994.r156194>

© 2022 Moenadjat Y. This is an open access peer review report distributed under the terms of the [Creative Commons Attribution License](#), which permits unrestricted use, distribution, and reproduction in any medium, provided the original work is properly cited.



Yefta Moenadjat 

Faculty of Medicine, Department of Surgery Cipto Mangunkusumo General Hospital, Universitas Indonesia, Jakarta, Indonesia

Thanks for the revision. The revision has been shown compared to the previous one. However, some must be revised and completed (please find the comment in the [sticky note](#)).

Competing Interests: No competing interests were disclosed.

I confirm that I have read this submission and believe that I have an appropriate level of expertise to confirm that it is of an acceptable scientific standard, however I have significant reservations, as outlined above.

Author Response 17 Dec 2022

Andry Irawan, Pelita Harapan University, Indonesia

Dear Dr Yefta Moenadjat,

Thank you for allowing us to submit a revised draft of our manuscript. We have adjusted several texts and sentences based on your highlighted texts. We also attempted to register the experimental study; however, all animal study registries must be submitted before the research is done. We sincerely regret this matter, and our evaluation will be for the following animal study.

We look forward to hearing from you regarding the submission, responses, questions, and comments you may have. Thank you.

Sincerely,
Andry Irawan

Competing Interests: We declared no competing interest within this study.

Version 1

Reviewer Report 23 September 2022

<https://doi.org/10.5256/f1000research.120607.r151185>

© 2022 Kurniawan A. This is an open access peer review report distributed under the terms of the [Creative Commons Attribution License](#), which permits unrestricted use, distribution, and reproduction in any medium, provided the original work is properly cited.



Andree Kurniawan 

Department of Internal Medicine, Faculty of Medicine, Pelita Harapan University, Tangerang, Indonesia

The authors have reported the basic science research regarding the the role of anti angiogenesis in HCC.

My comments are:

1. In the introduction may be added the recent update in HCC since there are emerging new data about anti angiogenesis and immunotherapy . may be added also the role of levantinib. Sorafenib nowadays is not a standard of care for advanced inoperable HCC. Atezo Bev was the standard of care.
2. Should be added also in the introduction the background rationale for this research since there are several studies about it already.
3. In the discussion should be added the implication for clinical practice the combination of experimental drugs. What is the implication for translation research from this data?
4. Advice for further basic research should be added, related to the limitations of this study.
5. In the discussion do not repeat the results, however, compare the results with other studies - similar results or different results ?

Is the work clearly and accurately presented and does it cite the current literature?

Partly

Is the study design appropriate and is the work technically sound?

Yes

Are sufficient details of methods and analysis provided to allow replication by others?

Yes

If applicable, is the statistical analysis and its interpretation appropriate?

Partly

Are all the source data underlying the results available to ensure full reproducibility?

Yes

Are the conclusions drawn adequately supported by the results?

Yes

Competing Interests: No competing interests were disclosed.

Reviewer Expertise: HCC, epidemiology, cancer, hematology

I confirm that I have read this submission and believe that I have an appropriate level of expertise to confirm that it is of an acceptable scientific standard, however I have significant reservations, as outlined above.

Author Response 08 Nov 2022

Andry Irawan, Pelita Harapan University, Indonesia

Dear Dr Andree Kurniawan,

Thank you for allowing us to submit a revised draft of our manuscript titled *Anti-angiogenic effect of the combination low-dose sorafenib and EGCG in HCC-induced Wistar rats*. We appreciate the time and effort you have dedicated to providing your valuable feedback on our manuscript. We are grateful to the reviewer for their insightful comments on our paper. We have been able to incorporate changes to reflect most of the suggestions provided by the reviewer. We have highlighted the changes within the manuscript.

Here is a point-by-point response to the reviewer's comments and concerns.

1. In the introduction may be added the recent update in HCC since there are emerging new data about anti angiogenesis and immunotherapy may be added also the role of levantinib. Sorafenib nowadays is not a standard of care for advanced inoperable HCC. Atezo Bev was the standard of care.

Author's comment: We have incorporated the additional statement in the second last paragraph of the introduction.

2. Should be added also in the introduction the background rationale for this research since there are several studies about it already.

Author's comment: The research rationale has been stated in the 3rd paragraph of the

introduction.

3. In the discussion should be added the implication for clinical practice the combination of experimental drugs. What is the implication for translation research from this data?

Author's comment: The combination of low-dose Sorafenib with EGCG has a more potential anti-angiogenic effect in liver cancer by reducing VEGF values compared to the single standard-dose Sorafenib. We can advance the research into human, but firstly we need to examine the toxicity effect in animal research.

4. Advice for further basic research should be added, related to the limitations of this study.

Author's comment: The advice for further studies has been mentioned in the limitation section of the discussion.

5. In the discussion do not repeat the results, however, compare the results with other studies - similar results or different results?

Author's comment: The comparison with other studies has been incorporated in the 4th paragraph of the discussion.

We look forward to hearing from you in due time regarding the submission, responses, further questions, and comments you may have. Thank you.

Sincerely,
Andry Irawan

Competing Interests: The Authors declared no competing interests related to this study

Author Response 17 Dec 2022

Andry Irawan, Pelita Harapan University, Indonesia

Dear Dr. Yefta Moenadjat,

Thank you for allowing us to submit a revised draft of our manuscript. We have adjusted several texts and sentences based on your highlighted texts. We also attempted to register the experimental study; however, all animal study registries must be submitted before the research is done. We sincerely regret this matter, and our evaluation will be for the following animal study.

We look forward to hearing from you regarding the submission, responses, questions, and comments you may have. Thank you.

Sincerely,

Andry Irawan

Competing Interests: We declared no competing interests within this study.

Reviewer Report 22 June 2022

<https://doi.org/10.5256/f1000research.120607.r141158>

© 2022 Moenadjat Y. This is an open access peer review report distributed under the terms of the [Creative Commons Attribution License](#), which permits unrestricted use, distribution, and reproduction in any medium, provided the original work is properly cited.



Yefta Moenadjat 

Faculty of Medicine, Department of Surgery Cipto Mangunkusumo General Hospital, Universitas Indonesia, Jakarta, Indonesia

1. The abstract

- Abstract reflects the information of the content. The first statement in the background was not in line with the texts elsewhere in the content. In addition, the study was not dealing with the cost and benefit but the efficacy. Then why do the authors put an irrelevant statement here?
- The method section in the abstract comprises a brief description of the study design and PICO. Consider revising.
- In the results section of an abstract, it is better to provide the interpretation of the findings in the study rather than providing statistical analysis. In addition, it will be better to put an attribute (for instance, group I, II, III, and control) rather than X1, X2, confusing the readers.
- Results session: Please consider using English formatting correctly. English does not use a comma but a point for decimals.
- The abstract's conclusion differs from the conclusion written in the body and is not in line with the study's title and aim, which is focused on the anti-angiogenic effect. Therefore, consider being consistent with it.

2. Introduction

- The second paragraph:
 - Are the statement in the first three sentences referred to as the same reference as the fourth sentence?
 - There is an interplay of some factors, including VEGF inducing cancer - including HCC - and not solely VEGF. Consider elaborating a little bit regarding this. It does not matter if the authors solely focus on VEGF.
 - Consistency is essential in scientific publication. Therefore, consider using 'level' consistently instead of using a different term of 'concentration' or 'values' in this manuscript.
- The third paragraph:
 - Is surgery the most common procedure, or is it a primary or definitive procedure?
 - The author stated: "...while chemotherapy and targeted therapy are also used." The question is: Is it 'also used' or is it the protocol for the HCC?

- The fourth paragraph:
 - Instead of providing information from previous studies reporting improvement in the prognosis of HCC, the authors should propose the rationale for using this drug to suppress VEGF.
 - It is essential to answer the question of why use this drug.
 - Authors should provide information on why using the rat model. Particularly the HCC-induced model.
 - There is no information about using DEN in the background that presents the transparency of using DEN to induce HCC.
 - Consider providing such information about toxicity and carcinogenesis effect briefly. Not all readers know about this.
- The fifth paragraph:
 - The statement was not in line with the structure following the checklist. In addition, the link provided indicating the ARRIVE checklist is the same as provided in ARRIVE guidelines <https://arriveguidelines.org/> but not specific for this study.

3. Methods

- Describe systematically and sequentially:
 - Study design, division of groups in randomization (including randomization process, random? who did the randomization? what was the instrument used for this purpose?)
 - Preparation of animals and pre-intervention treatment,
 - Intervention detail in each group,
 - Preparation of materials/materials.
- Next, the treatment consists of:
 - The carcinogenesis induction process. Who judges the successful induction, and how did it assess, showing that the intervention was successful? How long does it take to determine that the induction process was successful?
- Describe further detail of tumor-induced DEN characteristics that are similar to an HCC.
- This section does not explain when Sorafenib and ECGC are given. Either immediately or wait until the HCC induction procedure has been successful. Although, it was explained that the specimens were taken ten weeks after administering these two drugs.
- The authors did not describe the specific area of the taken specimen but 'liver tissue'. Was it taken from a tumor mass?
- Describe further detail of method in systematic order.

4. Results. Use the same terminology that commented in the introduction and method. Consider providing the findings, but not the interpretation.

5. Discussion. Use the same terminology that commented in the introduction and method.

6. Conclusion. Use the same terminology that commented in the introduction and method.

Is the work clearly and accurately presented and does it cite the current literature?

Partly

Is the study design appropriate and is the work technically sound?

Partly

Are sufficient details of methods and analysis provided to allow replication by others?

Partly

If applicable, is the statistical analysis and its interpretation appropriate?

Partly

Are all the source data underlying the results available to ensure full reproducibility?

Partly

Are the conclusions drawn adequately supported by the results?

Partly

Competing Interests: No competing interests were disclosed.

I confirm that I have read this submission and believe that I have an appropriate level of expertise to confirm that it is of an acceptable scientific standard, however I have significant reservations, as outlined above.

Author Response 22 Sep 2022

Andry Irawan, Pelita Harapan University, Indonesia

Dear Dr Yefta Moenadjat,

Thank you for allowing us to submit a revised draft of our manuscript titled *Anti-angiogenic effect of the combination low-dose sorafenib and EGCG in HCC-induced Wistar rats*. We appreciate the time and effort you have dedicated to providing your valuable feedback on our manuscript. We are grateful to the reviewer for their insightful comments on our paper. We have been able to incorporate changes to reflect most of the suggestions provided by the reviewer. We have highlighted the changes within the manuscript.

Here is a point-by-point response to the reviewer's comments and concerns.

1. THE ABSTRACT

- Abstract reflects the information of the content. The first statement in the background was not in line with the texts elsewhere in the content. In addition, the study was not dealing with the cost and benefit but the efficacy. Then why do the authors put an irrelevant statement here?
- The method section in the abstract comprises a brief description of the study design and PICO. Consider revising.
- In the results section of an abstract, it is better to provide the interpretation of the findings in the study rather than providing statistical analysis. In addition, it will be better to put an attribute (for instance, group I, II, II, and control) rather than X1, X2, confusing the readers.
- Results session: Please consider using English formatting correctly. English does not use a comma but a point for decimals.
- The abstract's conclusion differs from the conclusion written in the body and is not in line with the study's title and aim, which is focused on the anti-angiogenic effect.

Therefore, consider being consistent with it.

Author's comment: *Thank you for your concern. We have revised the abstract section into a more relevant statement.*

2. INTRODUCTION

The second paragraph:

- Are the statement in the first three sentences referred to as the same reference as the fourth sentence?

Author's comment: Yes, they referred to the same reference.

- There is an interplay of some factors, including VEGF inducing cancer - including HCC - and not solely VEGF. Consider elaborating a little bit regarding this. It does not matter if the authors solely focus on VEGF
- Consistency is essential in scientific publication. Therefore, consider using 'level' consistently instead of using a different term of 'concentration' or 'values' in this manuscript.

Author's comment: *Thank you for your positive feedback. We have elaborated the interplay factors and revised the 'concentration' or 'values' into 'level' terms.*

The third paragraph:

- Is surgery the most common procedure, or is it a primary or definitive procedure?

Author's comment: Yes, surgery is the definitive treatment for HCC if it is operable

- The author stated: "...while chemotherapy and targeted therapy are also used." The question is: Is it 'also used' or is it the protocol for the HCC?

Author's comment: Yes, it is the protocol for unresectable HCC

The fourth paragraph:

- Instead of providing information from previous studies reporting improvement in the prognosis of HCC, the authors should propose the rationale for using this drug to suppress VEGF.
- It is essential to answer the question of why use this drug.
- Authors should provide information on why using the rat model. Particularly the HCC-induced model.
- There is no information about using DEN in the background that presents the transparency of using DEN to induce HCC.
- Consider providing such information about toxicity and carcinogenesis effect briefly. Not all readers know about this.

Author's comment: Thank you for your considerate question. We have incorporated all the questions stated above within the manuscript.

The fifth paragraph:

- The statement was not in line with the structure following the checklist. In addition, the link provided indicating the ARRIVE checklist is the same as provided in ARRIVE guidelines <https://arriveguidelines.org/> but not specific for this study.

Author's comment: The ARRIVE checklist is available in the reporting guideline section. Zenodo: ARRIVE checklist for 'Anti-angiogenic effect of the combination low-dose sorafenib and EGCG in HCC-induced Wistar rats.' <https://doi.org/10.5281/zenodo.6044890>.

3. METHODS

Describe systematically and sequentially:

- Study design, division of groups in randomization (including randomization process, random? who did the randomization? what was the instrument used for this purpose?)

Author's comment: This study was a double-blind, randomized control trial. A laboratory analyst performed randomization into four groups.

- Preparation of animals and pre-intervention treatment,
- Intervention detail in each group,
- Preparation of materials/materials.

Author's comment: Thank you for your insightful comments. We have incorporated the additional statement in the methods section.

Next, the treatment consists of:

- The carcinogenesis induction process. Who judges the successful induction, and how did it assess, showing that the intervention was successful? How long does it take to determine that the induction process was successful?

Author's comment: An anatomical pathologist from Dr Mintoharjo Naval Hospital determined the successful induction under the microscope and required ten weeks to confirm the accomplishment of the induction.

- Describe further detail of tumor-induced DEN characteristics that are similar to an HCC.

Author's comment: We have elaborated on the similarity of the tumor-induced DEN and HCC characteristics.

- This section does not explain when Sorafenib and ECGC are given. Either immediately or wait until the HCC induction procedure has been successful. Although, it was explained that the specimens were taken ten weeks after administering these two drugs.

Author's comment: Sorafenib and ECGC were given until the HCC induction procedure was successful by the result from the anatomical pathologist successfully succeeded.

- The authors did not describe the specific area of the taken specimen but 'liver tissue'. Was it taken from a tumor mass?

Author's comment: Yes, we took the whole liver tissue-contained tumor masses

- Describe further detail of method in systematic order.

Author's comment: We have amended the method section more systematically.

We look forward to hearing from you in due time regarding the submission, responses, further questions, and comments you may have. Thank you.

Sincerely,
Andry Irawan

Competing Interests: We declared no competing interests within our study.

The benefits of publishing with F1000Research:

- Your article is published within days, with no editorial bias
- You can publish traditional articles, null/negative results, case reports, data notes and more
- The peer review process is transparent and collaborative
- Your article is indexed in PubMed after passing peer review
- Dedicated customer support at every stage

For pre-submission enquiries, contact research@f1000.com

F1000Research